

## Compassionate mesenchymal stem cell treatment in a severe COVID-19 patient: a case report

COVID-19 presentations range from cold-like symptoms to severe symptoms with the development of acute respiratory distress syndrome (ARDS). We report on a severe COVID-19 patient who was mechanically ventilated and who developed ARDS and bacterial infection. Because of rapid clinical deterioration and the exhaustion of other treatment options, the family and attending physicians requested a compassionate use of adult allogeneic bone marrow-derived mesenchymal stem cells (MSC) in addition to commonly used immunosuppressive, antiviral, and supportive therapy. The clinical course is discussed thoroughly, with a special emphasis on the safety and effect of MSC therapy. Compassionate MSC treatment, given in three rounds, affected ARDS regression. The patient was discharged from the intensive care unit after 31 days and from hospital after 49 days in a good general condition. MSC treatment was not associated with any side effects and was well tolerated in a three-week period; therefore, it should be studied in larger trials and considered for compassionate use.

Dragan Primorac<sup>1,2,3,4,5,6,7,8</sup>, Sanda Stojanović Stipičić<sup>4,9</sup>, Marko Strbad<sup>10,11</sup>, Lenart Girandon<sup>10</sup>, Ariana Barlič<sup>10</sup>, Mileva Frankić<sup>9</sup>, Ivo Ivčić<sup>4,12</sup>, Daniela Marasović Krstulović<sup>4,13</sup>, Irena Jukić<sup>14</sup>, Beata Halassy<sup>15,16</sup>, Ana Hećimović<sup>14</sup>, Vid Matišić<sup>1</sup>, Vilim Molnar<sup>1</sup>

<sup>1</sup>St. Catherine Specialty Hospital, Zagreb/Zabok, Croatia

<sup>2</sup>Eberly College of Science, The Pennsylvania State University, University Park, State College, PA, USA

<sup>3</sup>The Henry C. Lee College of Criminal Justice and Forensic Sciences, University of New Haven, West Haven, CT, USA

<sup>4</sup>Medical School, University of Split, Split, Croatia

<sup>5</sup>School of Medicine, Faculty of Dental Medicine and Health, Josip Juraj Strossmayer University Osijek, Osijek, Croatia

<sup>6</sup>School of Medicine, Josip Juraj Strossmayer University Osijek, Osijek, Croatia

<sup>7</sup>Faculty of Medicine University of Rijeka, Rijeka, Croatia

<sup>8</sup>Medical School REGIOMED, Coburg, Germany

<sup>9</sup>Department of Anesthesiology and Intensive Care, Clinical Hospital Split, Split, Croatia

<sup>10</sup>Educell Ltd., Trzin, Slovenia

<sup>11</sup>Biobanka Ltd, Trzin, Slovenia

<sup>12</sup>Department of Infectious Diseases, University Hospital Split, Split, Croatia

<sup>13</sup>Department of Internal Medicine, University Hospital Split, Split, Croatia

<sup>14</sup>Croatian Institute of Transfusion Medicine, Zagreb, Croatia

<sup>15</sup>Center for Research and Knowledge Transfer in Biotechnology, University of Zagreb, Zagreb, Croatia

<sup>16</sup>Center of Excellence for Virus Immunology and Vaccines, CERVirVac, Zagreb, Croatia

Received: March 11, 2021

Accepted: May 5, 2021

**Correspondence to:**

Dragan Primorac  
St. Catherine Specialty Hospital  
Trpinjska 7  
10000 Zagreb, Croatia  
[draganprimorac2@gmail.com](mailto:draganprimorac2@gmail.com)

We report on a case of severe COVID-19 in a 50-year-old male patient who was treated with an infusion of parenteral mesenchymal stem cells (MSC) (Table 1). The pathophysiologic mechanism of COVID-19 is not yet fully understood, but some patients experience a strong immune response, with a release of pro-inflammatory cytokines and chemokines causing a "cytokine storm." These patients present with a severe clinical course, acute respiratory distress syndrome (ARDS), and require mechanical respiratory support (1,2). Studies investigating MSC in COVID-19 treatment have shown good results in reducing the serum levels of pro-inflammatory cytokines and chemokines, which are the main driver of ARDS in these patients (3).

### CASE REPORT

The patient first presented to the emergency department of University Hospital Split, Križine, after five days of home isolation and COVID-19 treatment. He had a fever of up to 38.5 °C, myalgia, and diarrhea. As a medical doctor in the same hospital, the patient had been in contact with COVID-19 patients and coworkers. Medical history was unremarkable and no chronic medical conditions were reported. Before admission, the patient was treated for five days with antipyretics, which resolved fever, and azithromycin. Upon the first hospital presentation, he was eupneic, with blood oxygen saturation ( $Sa_{O_2}$ ) of 97%. The laboratory results indicated a barely increased C-reactive protein (CRP) of 11.3 mg/L. A chest x-ray showed bilateral basal and perihilar opacifications. The patient was released for home treatment, with prescribed 32 mg methylprednisolone for seven days in a de-escalating pattern.

Four days later, the patient visited the emergency department again, with worsening symptoms (fever over 39 °C and dry cough). In between the hospital visits, methylprednisolone dose was escalated to 64 mg and amoxicillin and clavulanic acid were added after finishing azithromycin.  $Sa_{O_2}$  upon the second presentation was 94%. Laboratory tests (Table 2) indicated elevated leukocytes ( $10.9 \times 10^9/L$ ) with neutrophil predominance (90.4%, lymphocytes 5.7%) and mildly elevated CRP of 24.9 mg/L. A native chest CT showed extensive bilateral ground-glass opacities (Figure 1). Due to clinical and radiologic worsening, the patient was admitted to a specialized COVID-19 ward, where he was administered remdesivir (200 mg iv for five days), methylprednisolone 240 mg, enoxaparin 0.6 mL, moxifloxacin 400 mg, and supportive therapy. Oxygen supplementation was started the next day with 2 L/min nasal cannula. On the third day of hospitalization, blood oxygen saturation

decreased ( $Sa_{O_2}$  91%), and high-flow oxygen therapy (35 L/min) was started.

On the sixth day of hospitalization, the patient was dyspneic. Laboratory findings suggested an increased inflammatory response, with  $Sa_{O_2}$  87% (Table 2). CT pulmonary angiography showed no signs of pulmonary embolism, but it did show a progression of bilateral consolidations (Figure 1). High-flow oxygen was increased to 45 L/min. On the same day, the patient was examined for severe thrombocytopenia ( $10 \times 10^9/L$ ) by a hematologist, who diagnosed immunogenic thrombocytopenia, administered intravenous immunoglobulins (400 mg/kg for 5 days), and changed the dose of methylprednisolone to 100 mg.

On the seventh day of hospitalization, the patient was referred to the COVID-19 intensive care unit (ICU), where he was sedated, intubated, and started mechanical ventilation (synchronized intermittent mandatory ventilation f/24min, TV 440 mL; first  $FiO_2$  100%, then gradually decreased to 80%) in a prone position, which improved blood oxygenation. On the same day,  $FiO_2$  was gradually reduced to 50%. Bronchoscopy, performed the following day, was unremarkable. The D-dimer levels were immeasurably high ( $>35.2$  mg/L) (Table 2). The patient was given a dose of COVID-19 convalescent plasma (CCP). The plasma was obtained in the Croatian Institute of Transfusion Medicine from a healthy donor with a documented history of SARS-CoV-2 infection who had been asymptomatic for  $\geq 28$  days and was specified eligible according to standard blood donor criteria. SARS-CoV-2 neutralizing antibodies in CCP were quantified by infective-virus neutralization assay, using a reference calibrated according to the First WHO International Standard for anti-SARS-CoV-2 immunoglobulin (human) (NIBSC code 20/136, NIBSC, Potters Bar, UK), so the titer is expressed in international units per milliliter (IU/mL) (4). The volume of the CCP dose used for therapy was 200 mL, and the titer of neutralizing antibodies was 242 IU/mL.

Since all conventional and recognized therapies had been exhausted, the hospital ethics committee and drug committee approved the use of MSC compassionate treatment upon the request of the attending physicians and after obtaining written consent from the patient's wife. During the ICU stay, the patient was given three doses of Immu-ART™ (Educell Ltd, Trzin, Slovenia, member of Medical Biobank Swiss Institute SA), allogenic, HLA-incompatible, and non-related bone marrow-derived MSC. The first dose ( $10^6$  cells/kg) was administered intravenously on the ninth

TABLE 1. Timeline of the disease and treatment course

Day of hospitalization	Clinical, radiological, and laboratory findings
1st day of the disease	<p>First presented to the emergency department of a regional COVID-19 center after five days of home isolation and COVID-19 treatment.</p> <p>Symptoms: fever of up to 38.5 °C, myalgia, and diarrhea.</p> <p>Clinical findings: eupneic, blood oxygen saturation (Sao<sub>2</sub>) 97%.</p> <p>Laboratory results: elevated C-reactive protein (CRP) 11.3 mg/L.</p> <p>Chest x-ray: bilateral basal and perihilar opacifications.</p> <p>Treatment: released for home treatment with 32 mg methylprednisolone for 7 d in a de-escalating pattern.</p>
1st (4th day of the disease)	<p>Presented with worsening symptoms. Methylprednisolone dose escalated to 64 mg and added amoxicillin and clavulanic acid after finishing azithromycin.</p> <p>Symptoms: fever over 39 °C, dry cough</p> <p>Clinical findings: Sao<sub>2</sub> 94%.</p> <p>Laboratory results: elevated leukocytes (10.9 × 10<sup>9</sup>/L) with neutrophil predominance (90.4%, lymphocytes 5.7%), mildly elevated CRP 24.9.</p> <p>Chest computed tomography (CT): extensive bilateral ground-glass opacities.</p> <p>Treatment: admission to a specialized COVID-19 ward, remdesivir (200 mg iv), methylprednisolone 240 mg, enoxaparin 0.6 mL, moxifloxacin 400 mg, and supportive antipyretic therapy.</p>
2nd	Oxygen supplementation was started with 2 L/min nasal cannula.
3rd	The condition continued to worsen (Sao <sub>2</sub> 91%). High-flow oxygen therapy (35 L/min) initiated.
6th	<p>Clinical deterioration with dyspnea. Sao<sub>2</sub> 87%</p> <p>Laboratory findings suggested an increased inflammatory response and severe thrombocytopenia (10 × 10<sup>9</sup>/L).</p> <p>CT pulmonary angiography showed no signs of pulmonary embolism but showed a progression of bilateral consolidations.</p> <p>Treatment: high-flow oxygen increased to 45 L/min.</p> <p>Hematologist consulted: immunogenic thrombocytopenia. Intravenous immunoglobulins (400 mg/kg), methylprednisolone changed to 100 mg.</p>
7th	Referral to a COVID-19 intensive care unit (ICU). Mechanical ventilation started (synchronized intermittent mandatory ventilation f/24min, TV 440 mL; first FiO <sub>2</sub> 100%, then gradually decreased to 80%). FiO <sub>2</sub> was gradually reduced to 50% the same day.
8th	The patient was given a dose of convalescent plasma. Immeasurably high levels of D-dimers (>35.2 mg/L).
9th	The hospital ethics and drug committees approved mesenchymal stem cells (MSCs) compassionate treatment. The first dose of allogenic bone marrow-derived MSCs (10 <sup>6</sup> cells/kg) was given.
12th	<p>The second dose of allogenic bone marrow-derived MSCs was given.</p> <p>The patient was transferred to a tertiary hospital center for further treatment.</p> <p>The therapy was continued, and the patient was mechanically ventilated.</p>
13th	<p>Continued to clinically worsen. Sao<sub>2</sub> below 90%. Later the same day developed subcutaneous emphysema.</p> <p>Laboratory results: reduction of inflammatory parameters.</p> <p>Bronchoscopy: abundant yellowish secretion, sent for microbiologic evaluation.</p> <p>Chest CT: extensive airspace opacifications and pneumomediastinum.</p> <p>Low ventilation compliance (tidal volumes below 350 mL) with decreasing Sao<sub>2</sub> levels indicating acute respiratory distress syndrome.</p> <p>Microbiologic culture of the bronchial aspirate: methicillin-resistant <i>Staphylococcus aureus</i> and <i>Acinetobacter Baumannii</i>.</p> <p>Treatment: recruitment maneuver, high positive end-expiratory pressure (PEEP) (Hamilton-Intellivent ASV) with low driving pressure (below 14 cm H<sub>2</sub>O).</p> <p>PEEP was continuously reduced in the following days. Antibiotic treatment (colistin 9 million i.u. initially, the next and following days 2 × 4.5 million i.u., fosfomycin 3 × 8 g, and linezolid 2 × 600 mg)</p>
15th	<p>Repeated bronchoscopy showed the same findings.</p> <p>Chest x-ray: no reduction in subcutaneous emphysema.</p>
16th	<p>The third dose of allogenic bone marrow-derived MSCs was given.</p> <p>Chest x-ray: regression of opacifications.</p> <p>Later the same day paroxysmal hypertension &gt;200 mm Hg and tachycardia &gt;140/min.</p> <p>Echocardiography: analysis impeded by pneumomediastinum, normal left ventricle morphology, ejection fraction of 50%.</p>

TABLE 1. Continued. Timeline of the disease and treatment course

Day of hospitalization	Clinical, radiological, and laboratory findings
17th	The patient was extubated and put on high-flow oxygen (60 L/min).
19th	Clinical improvement. Oxygenation changed from high-flow oxygen to nasal cannula. Verticalized in the course of physical therapy.
20th	Lower urinary tract pain. Laboratory findings: bacteriuria. Blood cultures: positive for gram-negative bacilli. Treatment: ceftazidime/avibactam (3 × 2.5 g iv).
22nd	Clinically stable. Leukocytes returned to physiological levels.
23rd	Chest CT: regressive dynamic of airspace opacifications.
30th	Able to perform basic physical activities on his own. No oxygen supplementation needed. CRP levels normal. All antibiotics discontinued.
31st	Transferred to a clinic for physical medicine for further rehabilitation.
49th	Discharged from hospital.

day of hospitalization. MSC doses were prepared from the bone marrow of a young, healthy donor, who agreed to make the donation for allogeneic treatment. The donor was negative for viral markers (HBs Ag, HBc Ab, HCV Ab, HIV 1-2 Ab, TPHA, HBV NAT, HCV NAT, HIV NAT) according to EU legislation, Directive 2004/23/EC of the European Parliament and the Council of the European Union (the body setting the quality and safety standards for donation, procurement, testing, processing, preservation, storage, and distribution of human tissues and cells). The cells were prepared for hospital exemption use in a controlled and verified laboratory in a cleanroom facility in a class A safety cabinet following the guidelines and principles of good manufactured practice. The cultivated cells used in therapy showed morphological characteristics of MSC and expressed CD105, CD73, and CD90, but not CD45 and CD34. The patient's laboratory parameters were monitored daily, showing a decrease in D-dimer and CRP levels in a three-day period (Table 2).

The second MSC dose was given on the twelfth day of hospitalization. The treatment was continued in the non-COVID ICU, University Hospital Split, Firule, since the patient was no longer considered contagious. This is a standard protocol that allows freeing up hospital beds for the acutely ill contagious patients. The therapy and mechanical ventilation were maintained.

The next day, despite a marked reduction in leukocyte count and CRP level (Table 2),  $SaO_2$  fell below 90%. Bronchoscopy revealed an abundant yellowish secretion, which was sent for microbiologic evaluation. A repeated native CT of the

chest showed extensive airspace opacifications and pneumomediastinum (Figure 1). Ventilation compliance was low (tidal volumes below 350 mL), with decreasing  $SaO_2$  levels, which is why ARDS was considered the leading diagnosis. A recruitment maneuver was performed, and ventilation with high positive end-expiratory pressure (PEEP) was initiated (Intellivent ASV, Hamilton, Bonaduz, Switzerland) with low driving pressure (below 14 cm  $H_2O$ ). The same night, a subcutaneous emphysema was observed. PEEP was continuously reduced in the following days, with careful monitoring of the respiratory parameters. The microbiologic culture of the bronchial aspirate taken on the twelfth day was positive for methicillin-resistant *Staphylococcus aureus* and *Acinetobacter Baumannii*. Antibiotic treatment was started immediately based on the antibiogram (colistin 9 million i.u. initially, the next and following days 2 × 4.5 million i.u., fosfomycin 3 × 8 g, and linezolid 2 × 600 mg). Repeated bronchoscopy on the fifteenth day showed the same findings, and no reduction in subcutaneous emphysema was visible on the chest x-ray. The third MSCs dose was given on the sixteenth day of hospitalization. A chest x-ray showed the regression of opacifications. Later the same day, the patient experienced paroxysmal hypertension >200 mm Hg and tachycardia >140/min. Echocardiography, although impeded by pneumomediastinum, showed normal left ventricle morphology with an ejection fraction of 50%. On the seventeenth day, the patient was extubated and put on high-flow oxygen (60 L/min), with satisfying peripheral blood oxygen saturation.

The clinical condition continued to improve, and oxygen supplementation needs were lowering, with only nasal

cannula being sufficient on the nineteenth day of hospitalization. The patient was also able to verticalize in the course of physical therapy.

On the twentieth day, the patient complained of lower urinary tract pain. Urine samples (bacteriuria) suggested a urinary tract infection. Since blood cultures were positive for gram-negative bacilli, ceftazidime/avibactam (3×2.5 g iv) therapy was started.

In the following days, the condition was stable. Leukocytes returned to physiological levels on the twenty-second day of hospitalization. A chest CT performed on the twenty-third day of hospitalization showed a regressive dynamic of air-

space opacifications (Figure 1). CRP levels continued to decline and were normal on the thirtieth day of hospitalization, when all antibiotics were discontinued. The patient was able to perform basic physical activities on his own, without the need for oxygen supplementation, and on the thirty-first day of hospitalization was transferred to a physical medicine clinic. The patient remained in the hospital for an additional observation and rehabilitation period, after which he was discharged on the forty-ninth day of hospitalization.

## DISCUSSION

This case study describes the clinical course of the first Croatian patient treated with MSC for severe COVID-19. The

**TABLE 2.** The patient's key laboratory findings

Day of hospitalization	Leukocytes (10 <sup>9</sup> /L)	PT	D-dimers (mg/L)	Albumin (g/L)	CRP (mg/L)	Procalcitonin (ng/mL)	Ferritin (ng/mL)	LDH (U/L)
1st day of the disease	4.50	/	0.39	/	11.3	/	/	227.0
1st (4th day of the disease)	10.90	1.23	0.65	39.9	24.9	/	/	445
6th	17.30	1.01	21.9	27.0	17.0	0.08	1535	663
7th	14.40	0.78	>35.2	24.4	17.0	0.07	/	/
8th	15.30	0.94	>35.2	25.7	62.0	/	/	475
8th	15.90	/	/	/	/	/	/	/
9th	14.20	0.92	>35.2	24.9	35.8	0.08	/	/
	First round of MSC							
10th	16.7	0.95	>35.2	/	23.6	0.03	850	/
11th	17.2	1	31.98	24.4	37.6	0.16	/	324
12th	16	1.08	13.42	24.9	23.7	0.11	1.285	292
	Second round of MSC							
12th	15.1	1.1	16.44	27.3	20.5	0.11	1.008	305
13th	14.8	1.09	/	30.4	17.9	0.11	/	269
14th	12.9	1.21	/	31.8	58.9	0.14	/	/
16th	12.5	0.97	/	/	31	0.08	/	/
	Third round of MSC							
17th	11.1	0.75	/	29.3	25.1	0.1	/	/
18th	12	1.03	/	31.1	28.2	0.1	/	/
19th	17.2	1.01	7.33	34.3	25.7	0.09	2.154	389
20th	12.5	0.94	/	31.5	127.0	0.18	/	/
21st	13.5	0.97	/	33.8	89.9	0.15	/	/
22nd	9.8	0.87	/	33.8	77.2	0.15	/	/
23rd	7.9	/	12.5	/	56.0	0.12	/	/
24th	7.5	1.06	/	/	40.1	0.15	/	/
25th	6.4	0.94	/	32.3	26.2	0.11	/	/
26th	7.4	0.92	/	36.9	24.6	0.08	/	260
28th	9.2	/	/	/	8.7	0.07	/	/
30th	9.6	0.95	5.26	43.1	4.3	0.09	837	235

\*Abbreviations: PT – prothrombin time; CRP – C reactive protein; LDH – lactate dehydrogenase; MSC – mesenchymal stem cells; empty row – period of mechanical ventilation.

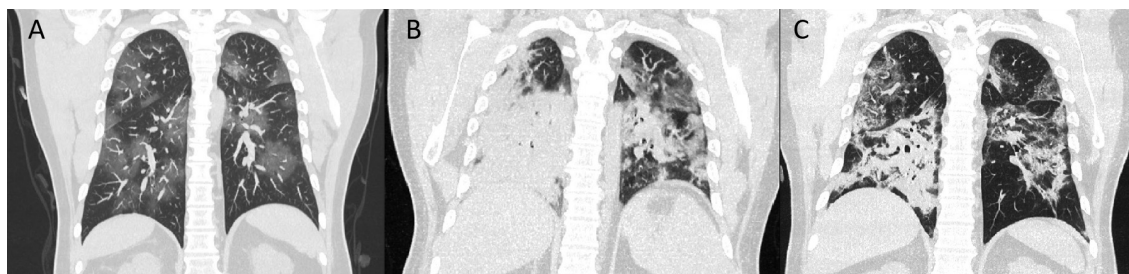
patient's clinical condition progressively worsened since admission and he eventually required mechanical ventilation. The treatment consisted of corticosteroids, immunoglobulins, and convalescent plasma, all of which were indicated due to their anti-inflammatory properties. No Croatian national guidelines on the use of CCP are currently available. In the present case, CCP was used due to its possible immunomodulatory effects, rather than due to its neutralizing antiviral effects (5). This decision was based upon FDA recommendations that the possible benefits of CCP outweigh the risks in critically ill COVID-19 patients (6). Remdesivir was also used, for 5 days.

Since the conventional therapeutic approach was unsuccessful, compassionate use of MSC therapy was initiated, following the Article 83 Regulation EC No 726/2004 of the European Parliament and Council of the European Union. Upon request of the attending physicians in University Hospital Split, Križine, and the patient's family, MSC were obtained from a young, living donor, and prepared as described previously. After our initial contact with Educell Ltd, all the relevant documentation on ImmunoART™ MSC harvesting, expansion, and delivery methods, as well as the opinion of the Slovenian drug regulating agency, was provided to the ethics committee of University Hospital Split. Croatian Ministry of Health was informed about the planned procedure. Meanwhile, Educell Ltd declared the use of MSC for humanitarian purposes, thereby providing them free of charge. No additional approvals were requested after the transfer to University Hospital Split, Firule, as both hospitals are considered a single administrative unit.

MSC are pluripotent stem cells differentiating into different mesodermic and non-mesodermic lineages. Their se-

cretome consists of immunomodulatory cytokines and chemokines, which were previously shown to modulate endothelial and epithelial permeability, promote endothelial repair, decrease scarring, and act anti-inflammatory (7). Autologous MSC are used in orthopedics for the treatment of osteoarthritis and have shown good results in pain reduction and increasing joint mobility, without any observed treatment-specific side effects (8-10).

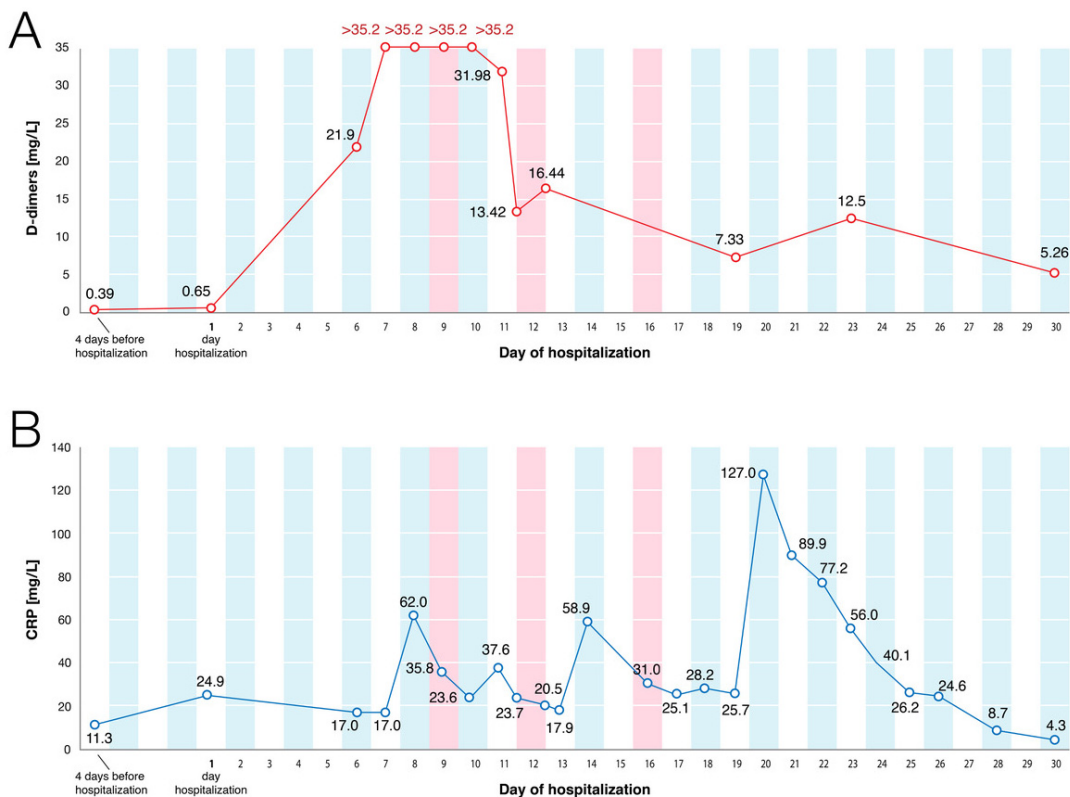
MSC are immune-privileged cells with a strong immunomodulatory (via IL-10, TGF $\beta$ , IDO, PGE2), antimicrobial (via antimicrobial peptide LL-37), and regenerative properties (via VEGF, KGF, EGF) (11,12). Preclinical studies have shown that after iv administration MSC remain "trapped" in the lung during the first passage, so, in the context of ARDS and COVID-19, they accumulate in the target tissue (13). Besides, MSC modulate the immune response via macrophages transition from an inflammatory M1 into an anti-inflammatory M2 phenotype (14,15). In addition, animal models showed the potential of their use for virus-induced pneumonia, ARDS, and lung failure treatment (16). At the moment of writing, *clinicaltrials.gov* lists 72 registered trials on MSC use in COVID-19 patients (17). Phase-one clinical trials have proven MSC therapy to be well tolerated and safe (11). A recent application of adipose tissue-derived MSC in 13 patients with severe COVID-19 pneumonia on medical ventilation significantly reduced the inflammatory parameters (CRP, IL-6, ferritin, LDH, D-dimer) (18). These findings are in line with those demonstrated in a systematic review and meta-analysis by Qu et al, who found no related serious adverse events after intravenous or intratracheal administration of allogenic MSC of various origin, as well as observed an improved lung function, radiographic findings, and inflammatory biomarkers level (19).



**FIGURE 1.** Chest computed tomography (CT) images (coronal reconstruction) at three time points. **(A)** Diffuse bilateral areas of ground glass opacities in all lobes at the first day of hospitalization. **(B)** Mixed airspace and ground glass opacities sparing only the lung apices at the thirteenth day of hospitalization. **(C)** Regression of airspace and ground glass opacities with fibrous changes in the right upper and middle lobe and left upper lobe at the twenty-third day of hospitalization.

In this case, after MSC administration we observed a reduction in leukocyte count, D-dimer levels, and CRP-levels, all of which are prognostic factors for COVID-19 severity (20-23) (Table 2, Figure 2). The D-dimer reduction was particularly impressive. A recent multicentric study demonstrated that elevated D-dimer levels (2.025 mg/L cutoff) correlate with poor prognosis (24). Despite the increased D-dimer levels, pulmonary angiography showed no signs of pulmonary embolism. However, the first MSC dose was applied a day after the convalescent plasma application, which can confound the interpretation of the observed effect. Nevertheless, the progressive clinical deterioration and the ARDS development were not stopped. The third MSC dose was applied on the sixteenth day of hospitalization and coincided with the radiographic regression of ARDS. The following day, the patient was extubated and switched to high-flow oxygen. These observations lead us to believe that MSC therapy may show a visible effect in a 24-hour period after administration, but the treatment is potential-

ly only effective in the setting of acute inflammatory conditions driven by cytokine storm, such as ARDS. However, we cannot confirm this observation because the required biomarkers were unavailable for analysis. This case did, however, demonstrate that compassionate MSC application was well tolerated after three treatment rounds, as no adverse events were observed that could be directly attributed to the procedure. Similar results were demonstrated in a case series by Hashemian et al, who reported a positive clinical effect (improved  $\text{Sao}_2$  and dyspnea) in 5 out of 11 patients who received prenatal (umbilical cord- and placenta-derived) MSC infusion in a two- to three-day period (25). The authors also reported a decrease in proinflammatory parameters (TNF-alpha, IL-6, IL-8, CRP) on the fifth day of treatment (24 hours after the third dose of MSCs). These parameters were not monitored in our patient, so we are unable to compare the results of the two studies (25). A prolonged hospital stay in COVID-19 patients can be complicated by hospital-acquired bacterial superinfections (26,27). The ex-



**FIGURE 2.** Inflammatory parameters by the day of hospitalization. (A) C-reactive protein (CRP); (B) D-dimers. The red lines represent the days when mesenchymal stem cells were applied.

act incidence of superinfections in Croatian hospitals has not been established, but they affect both the patient's prognosis and length of hospital stay (28). Our patient had a superinfection with *S. aureus* and *A. baumannii* confirmed in the bronchial aspirate upon bronchoscopy on day 12. We effectively treated the patient with colistin, fosfomycin, and linezolid. The second bacterial infection was found in blood cultures (gram-negative bacilli) on day 20, after the patient was already extubated and clinically improving. Ceftazidime/avibactam therapy was successful, and the patient's leukocyte count decreased to physiological levels in two days. These findings indicate the need for special attention when it comes to bacterial superinfections in COVID-19 patients, as they already have a weakened immune system. In our experience, the isolated specimens did not differ between COVID-19 and non-COVID-19 patients.

The main study limitations were the ability to obtain only the laboratory parameters used in daily clinical practice, which prevented us from analyzing the levels of cytokines driving the inflammatory response. Second, the use of convalescent plasma, remdesivir, and immunosuppressive drugs before MSC application prevent us from drawing independent conclusions on MSC efficacy. We were unable to exclude these factors, as MSC therapy has never before been used for COVID-19 treatment in Croatia, and the standard treatment protocols include the mentioned medications. Other limitations include a short follow-up and our inability to draw definite conclusions since the study was limited only to a single case. The observed effect of MSC in combination with readily used therapeutic measures should be further studied in larger patient cohorts and in centers able to perform more sophisticated laboratory analyses. However, since there is no currently available treatment for severe COVID-19, we propose MSC to be considered in patients who do not respond to commonly used therapeutic options.

**Acknowledgment** MSC treatment was made possible by the cooperation of Educell Ltd, St. Catherine Specialty Hospital, and the International Society for Applied Biological Sciences (ISABS).

**Funding** The convalescent plasma project was supported by the Croatian Science Foundation (grant IP-CORONA-04-2053 to BH) and by the European Regional Development Fund, grant number KK.01.1.1.01.0006, "Strengthening the Capacity of CerVirVac for Research in Virus Immunology and Vaccinology.

**Ethical approval** The patient gave written informed consent for the publication of data and images.

**Declaration of authorship** DP and SSS conceived and designed the study; DP, SSS, MS, LG, AB, MF, II, DMK, IJ, BH, and AH acquired the data; DP, SSS, II, VMa, and VMo analyzed and interpreted the data; DP, MS, IJ, BH, AH, VMa, and VMo drafted the manuscript; DP, SSS, MS, LG, AB, MF, II, DMK, VMa, and

VMo critically revised the manuscript for important intellectual content; all authors gave approval of the version to be submitted; all authors agree to be accountable for all aspects of the work.

**Competing interests** AH, BH, and IJ received grants by the Croatian Science Foundation (IP-CORONA-04-2053) and by the European Regional Development Fund, grant number KK.01.1.1.01.0006, "Strengthening the Capacity of CerVirVac for Research in Virus Immunology and Vaccinology. All authors have completed the Unified Competing Interest form at [www.icmje.org/coi\\_disclosure.pdf](http://www.icmje.org/coi_disclosure.pdf) (available on request from the corresponding author) and declare: no support from any organization for the submitted work; no financial relationships with any organizations that might have an interest in the submitted work in the previous 3 years; no other relationships or activities that could appear to have influenced the submitted work.

## References

- 1 Coperchini F, Chiovato L, Croce L, Magri F, Rotondi M. The cytokine storm in COVID-19: An overview of The involvement of The chemokine/chemokine-receptor system. *Cytokine Growth Factor Rev.* 2020;53:25-32. [Medline:32446778](#) [doi:10.1016/j.cytogfr.2020.05.003](#)
- 2 Chen N, Zhou M, Dong X, Qu J, Gong F, Han Y, et al. Epidemiological and clinical characteristics of 99 cases of 2019 novel coronavirus pneumonia in Wuhan, China: a descriptive study. *Lancet.* 2020;395:507-13. [Medline:32007143](#) [doi:10.1016/S0140-6736\(20\)30211-7](#)
- 3 Leng Z, Zhu R, Hou W, Feng Y, Yang Y, Han Q, et al. Transplantation of ACE2- mesenchymal stem cells improves the outcome of patients with COVID-19 pneumonia. *Aging Dis.* 2020;11:216-28. [Medline:32257537](#) [doi:10.14336/AD.2020.0228](#)
- 4 Rnjak D, Ravlić S, Šola A-M, Halassy B, Šemnički J, Šuperba M, et al. COVID-19 convalescent plasma as long-term therapy in immunodeficient patients? *Transfus Clin Biol.* 2021. [Medline:33901641](#) [doi:10.1016/j.traccli.2021.04.004](#)
- 5 Garraud O, Heshmati F, Pozzetto B, Lefrere F, Girot R, Saillol A, et al. Plasma therapy against infectious pathogens, as of yesterday, today and tomorrow. *Transfus Clin Biol.* 2016;23:39-44. [Medline:26775794](#) [doi:10.1016/j.traccli.2015.12.003](#)
- 6 Tanne JH. Covid-19: FDA approves use of convalescent plasma to treat critically ill patients. *BMJ.* 2020;26:368:m1256. [Medline:32217555](#) [doi:10.1136/bmj.m1256](#)
- 7 Brave H, MacLoughlin R. State of the art review of cell therapy in the treatment of lung disease, and the potential for aerosol delivery. *Int J Mol Sci.* 2020;21:6435. [Medline:32899381](#) [doi:10.3390/ijms21176435](#)
- 8 Primorac D, Molnar V, Rod E, Jeleč Ž, Čukelj F, Matišić V, et al. Knee Osteoarthritis: A review of pathogenesis and state-of-the-art non-operative therapeutic considerations. *Genes (Basel).* 2020;11:854. [Medline:32722615](#) [doi:10.3390/genes11080854](#)
- 9 Hudetz D, Boric I, Rod E, Jeleč Ž, Radić A, Vrdoljak T, et al. The effect of intra-articular administration of autologous microfragmented fat tissue with adipose-derived mesenchymal stem cells on proteoglycan synthesis in patients with knee osteoarthritis. *Genes (Basel).* 2017;8:270. [doi:10.3390/genes8100270](#)
- 10 Hudetz D, Jeleč Ž, Rod E, Boric I, Plečko M, Primorac D. The future



- of cartilage repair. In: Personalized medicine in healthcare systems: legal, medical and economic implications. Bodiřoga-Vukobrat N, Rukavina D, Pavelić K, Sander GG, editors. Cham: Springer Nature Switzerland; 2019. p. 375-411.
- 11 Durand N, Mallea J, Zubair AC. Insights into the use of mesenchymal stem cells in COVID-19 mediated acute respiratory failure. *NPJ Regen Med.* 2020;5:17. [Medline:33580031](#) [doi:10.1038/s41536-020-00105-z](#)
  - 12 Krasnodembskaya A, Song Y, Fang X, Gupta N, Serikov V, Lee JW, et al. Antibacterial effect of human mesenchymal stem cells is mediated in part from secretion of the antimicrobial peptide LL-37. *Stem Cells.* 2010;28:2229-38. [Medline:20945332](#) [doi:10.1002/stem.544](#)
  - 13 Fischer UM, Harting MT, Jimenez F, Monzon-Posadas WO, Xue H, Savitz SI, et al. Pulmonary passage is a major obstacle for intravenous stem cell delivery: the pulmonary first-pass effect. *Stem Cells Dev.* 2009;18:683-92. [Medline:19099374](#) [doi:10.1089/scd.2008.0253](#)
  - 14 de Witte SFH, Luk F, Sierra Parraga JM, Gargasha M, Merino A, Korevaar SS, et al. Immunomodulation by therapeutic mesenchymal stromal cells (MSC) is triggered through phagocytosis of MSC by monocytic cells. *Stem Cells.* 2018;36:602-15. [Medline:29341339](#) [doi:10.1002/stem.2779](#)
  - 15 Abumaree MH, Al Jumah MA, Kalionis B, Jawdat D, Al Khaldi A, Abomaray FM, et al. Human placental mesenchymal stem cells (pMSCs) play a role as immune suppressive cells by shifting macrophage differentiation from inflammatory M1 to anti-inflammatory M2 macrophages. *Stem Cell Rev Rep.* 2013;9:620-41. [Medline:23812784](#) [doi:10.1007/s12015-013-9455-2](#)
  - 16 Khatri M, Richardson LA, Meulia T. Mesenchymal stem cell-derived extracellular vesicles attenuate influenza virus-induced acute lung injury in a pig model. *Stem Cell Res Ther.* 2018;9:17. [Medline:29378639](#) [doi:10.1186/s13287-018-0774-8](#)
  - 17 National Library of Medicine (U.S.) Available from: <https://www.clinicaltrials.gov/ct2/results?recrs=&cond=Covid19&term=mesenchymal+stem+cells&cntry=&state=&city=&dist=>. Accessed: March 7, 2021.
  - 18 Sanchez-Guijo F, Garcia-Arranz M, Lopez-Parra M, Monedero P, Mata-Martinez C, Santos A, et al. Adipose-derived mesenchymal stromal cells for the treatment of patients with severe SARS-CoV-2 pneumonia requiring mechanical ventilation. A proof of concept study. *EClinicalMedicine.* 2020;25:100454. [Medline:32838232](#) [doi:10.1016/j.eclinm.2020.100454](#)
  - 19 Qu W, Wang Z, Hare JM, Bu G, Mallea JM, Pascual JM, et al. Cell-based therapy to reduce mortality from COVID-19: Systematic review and meta-analysis of human studies on acute respiratory distress syndrome. *Stem Cells Transl Med.* 2020;9:1007-22. [Medline:32472653](#) [doi:10.1002/sctm.20-0146](#)
  - 20 Carubbi F, Salvati L, Alunno A, Maggi F, Borghi E, Mariani R, et al. Ferritin is associated with the severity of lung involvement but not with worse prognosis in patients with COVID-19: data from two Italian COVID-19 units. *Sci Rep.* 2021;11:4863. [Medline:33649408](#) [doi:10.1038/s41598-021-83831-8](#)
  - 21 Huang I, Pranata R, Lim MA, Oehadian A, Alisjahbana B. C-reactive protein, procalcitonin, D-dimer, and ferritin in severe coronavirus disease-2019: a meta-analysis. *Ther Adv Respir Dis.* 2021;14:1753466620937175. [Medline:32615866](#)
  - 22 Singh K, Mittal S, Gollapudi S, Butzmann A, Kumar J, Ohgami RS. A meta-analysis of SARS-CoV-2 patients identifies the combinatorial significance of D-dimer, C-reactive protein, lymphocyte, and neutrophil values as a predictor of disease severity. *Int J Lab Hematol.* 2020. [Medline:33010111](#) [doi:10.1111/ijlh.13354](#)
  - 23 Mueller AA, Tamura T, Crowley CP, DeGrado JR, Haider H, Jezmir JL, et al. Inflammatory biomarker trends predict respiratory decline in COVID-19 patients. *Cell Rep Med.* 2020;1:100144. [Medline:33163981](#) [doi:10.1016/j.xcrm.2020.100144](#)
  - 24 He X, Yao F, Chen J, Wang Y, Fang X, Lin X, et al. The poor prognosis and influencing factors of high D-dimer levels for COVID-19 patients. *Sci Rep.* 2021;11:1830. [Medline:33469072](#) [doi:10.1038/s41598-021-81300-w](#)
  - 25 Hashemian SR, Aliannejad R, Zarrabi M, Soleimani M, Vosough M, Hosseini SE, et al. Mesenchymal stem cells derived from perinatal tissues for treatment of critically ill COVID-19-induced ARDS patients: a case series. *Stem Cell Res Ther.* 2021;12:91. [Medline:33514427](#) [doi:10.1186/s13287-021-02165-4](#)
  - 26 Garcia-Vidal C, Sanjuan G, Moreno-García E, Puerta-Alcalde P, Garcia-Pouton N, Chumbita M, et al. Incidence of co-infections and superinfections in hospitalized patients with COVID-19: a retrospective cohort study. *Clin Microbiol Infect.* 2021;27:83-8. [Medline:32745596](#) [doi:10.1016/j.cmi.2020.07.041](#)
  - 27 Falcone M, Tiseo G, Giordano C, Leonildi A, Menichini M, Vecchione A, et al. Predictors of hospital-acquired bacterial and fungal superinfections in COVID-19: a prospective observational study. *J Antimicrob Chemother.* 2021;76:1078-84. [Medline:33374002](#) [doi:10.1093/jac/dkaa530](#)
  - 28 Chaari A, Mnif B, Bahloul M, Mahjoubi F, Chtara K, Turki O, et al. *Acinetobacter baumannii* ventilator-associated pneumonia: epidemiology, clinical characteristics, and prognosis factors. *Int J Infect Dis.* 2013;17:1225-8. [Medline:24094525](#) [doi:10.1016/j.ijid.2013.07.014](#)